



PATIENT PRESENTING CLINICAL SIGNS

Monkey Raver Lethargy and exercise intolerance - r/o systemic infection, anemia, cardiac disease, metabolic disease
Intermittent coughing and licking - r/o upper respiratory infection, nausea, tracheal irritation

SPECIES

Feline

RADIOGRAPHIC STUDY OF THE THORAX

Right/ left lateral and ventrodorsal views of the thorax totaling 3 images available for review.

BREED

RADIOGRAPHIC FINDINGS

Terrier Mix The cardiac silhouette is within normal size limits with a vertebral heart score of ~ 9. No significant cardiac chamber enlargement is seen.

SEX

FS

The pulmonary vessels are normal in size and distribution. Lung fields are well aerated with no evidence of focal pulmonary infiltrates, nodules, mass lesions, edema, alveolar or interstitial consolidations.

AGE

6yr

The trachea is normal in diameter, course and position. No radiographic evidence of trachea collapse is identified.

The mediastinum is unremarkable. No pleural effusion is seen.

INTERPRETED BY

Nele Eley (Ondreka),
DVM Dr. med. vet.,
DipECVDP

There are no significant osseous abnormalities identified within the included portions of the thorax.

RADIOGRAPHIC DIAGNOSIS

- Normal radiographic presentation of the thorax with no radiographic evidence of cardiovascular or bronchopulmonary pathology

HOSPITAL NAME

Green Dog Dental
Wellness

INTERPRETATION OF FINDINGS & FURTHER RECOMMENDATIONS

The radiographic study reveals no evidence of cardiopulmonary disease. No evidence of pneumonia, edema, nodular lung disease, pleural disease or significant tracheal abnormalities identified to explain the reported lethargy, exercise intolerance and intermittent coughing.

REFERRING VET

Dr Rally

Further investigation for non-thoracic causes, upper airway disease, GI disease, metabolic disorders or early cardiac disease not detectable radiographically may be warranted. Early bronchopulmonary disease cannot be completely excluded as radiographic abnormalities may lag behind the onset of clinical signs in some conditions.

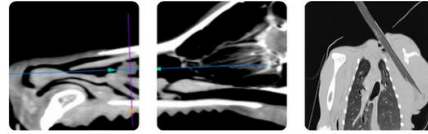
INVOICE

25009

If clinical signs persist or worsen repeat radiographs within 24 to 72 hours or additional diagnostics may be considered.

DATE

06/02/2026



PATIENT

Monkey Raver

SPECIES

Feline

BREED

Terrier Mix

SEX

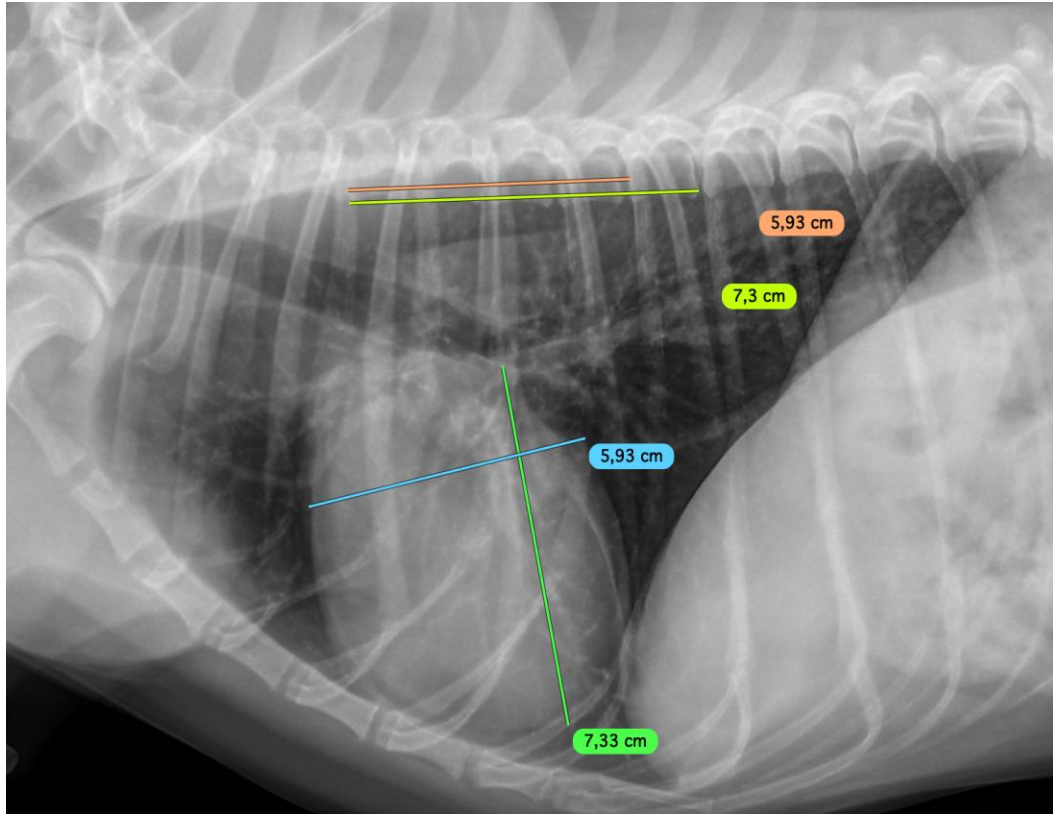
FS

AGE

6yr

INTERPRETED BY

Nele Eley (Ondreka),
DVM Dr. med. vet.,
DipECVDI



The information and recommendations provided are based on the images presented by the referring veterinarian. No evaluation can be communicated regarding pathology that was not visible in the image/video clips provided.

HOSPITAL NAME

Green Dog Dental
Wellness

Thank you for this referral. If the clinical or image interpretation does not parallel your findings or if I can be of any further assistance please contact me.

REFERRING VET

Dr Rally

Nele Eley (Ondreka), DVM, Dr. med. vet., DipECVDI
European Specialist in Veterinary Diagnostic Imaging, Cert. Radiology,
Senior lecturer University of Giessen/Germany, Veterinary Faculty, Department of Radiology.
info@sonopath.com

INVOICE

25009

DATE

06/02/2026



PATIENT

Monkey Raver

SPECIES

Feline

BREED

Terrier Mix

SEX

FS

AGE

6yr

INTERPRETED BY

Nele Eley (Ondreka),
DVM Dr. med. vet.,
DipECVDI

HOSPITAL NAME

Green Dog Dental
Wellness

REFERRING VET

Dr Rally

INVOICE

25009

DATE

06/02/2026